▼Table 12–6.2 Typical Pneumonia Pathogens

Typical Pneumonia Pathogens	High-Yield Comments
Viruses	
Rhinovirus	• Most common cause of the common cold • Most commonly transmitted by hand-to-eye and hand-to-nose contact • Other common causes of colds include coronavirus, adenovirus, influenza C virus, and coxsackievirus (may cause fever with pleuritis called acute chest syndrome)
Respiratory syncytial virus	• Most common cause of pneumonia and bronchiolitis (wheezing) in infants • Hand-washing and use of gloves prevents nosocomial outbreaks in nurseries • Infections primarily occur in winter • Rapid diagnosis by detection in nasopharyngeal wash • Passive immunization with palivizumab reduces hospitalization rates from November-April
Parainfluenza	• Most common cause of croup in infants: — Inspiratory stridor (upper airway obstruction) due to submucosal edema in trachea; brassy cough; signs of respiratory distress — Anterior x-ray of neck shows "steeple-sign," representing mucosal edema in the trachea (site of obstruction) • Bronchiolitis in infants • Treatment: Cold water humidifiers and aerosolized racemic epinephrine
Cytomegalovirus 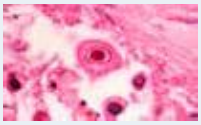	• Immunocompromised patient • Eosinophilic intranuclear inclusion
Influenzavirus	• Type A are most often involved • Hemagglutinins bind virus to cell receptors in the nasal passages • Neuraminadase dissolves mucus and facilitates release of viral particles • Influenza A: Worldwide epidemics; pneumonia may be complicated by a superimposed bacterial pneumonia, usually *Staphyloccous aureus* • Influenza B: Causes major outbreaks • Antigen drift: Minor mutation; does not require a new vaccine • Antigen shift: Major mutation in hemagglutinin or neuraminidase; new vaccine required • Clinical: Fever, headache, cough, myalgias, chest pain • Vaccination is mandatory for people >65 • Treatment: Neuraminidase inhibitors (e.g., oseltamivir) • Association with: Reye syndrome; Guillain-Barré syndrome
Hantavirus pulmonary syndrome	• Inhalation of urine/feces from deer mice in southwestern U.S. • Associated with ARDS, renal failure
Rubeola	• Fever, cough, conjunctivitis, and excessive nasal production • Koplik spots in the mouth precede onset of the rash • Warthin-Finkeldey multinucleated giant cells are a characteristic finding
Severe Acute Respiratory Syndrome (SARS) coronavirus	• First transmitted to humans through contact with masked palm civets (China) and then from human-to-human contact through respiratory secretions (e.g., hospitals, families) • Develop severe respiratory infection • Diagnose with viral detection by PCR assay detection of antibodies

Photo Credits: Dr. Gladden Willis/Visuals Unlimited, Inc

© DeVry/Becker Educational Development Corp. All rights reserved.

▼Table 12–6.2 Typical Pneumonia Pathogens *(continued)*

Typical Pneumonia Pathogens	High-Yield Comments
Bacteria	
Mycoplasma pneumoniae	• Most common cause of atypical pneumonia • Common in adolescents and military recruits (closed spaces) • Preceding condition for Guillain-Barré syndrome • Insidious onset with low-grade fever • Chest x-ray may show reticulonodular lesions • Complications: Bullous myringitis, cold AIHA • Treatment: Erythromycin; azithromycin; clarithromycin
Chlamydia trachomatis 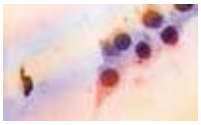	Responsible for afebrile pneumonia in newborns with staccato (choppy) cough, wheezing
Chlamydophila pneumoniae	Second most common cause of atypical pneumonia
Staphylococcus aureus 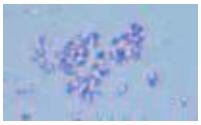	• Commonly superimposed on influenza and measles pneumonia • Productive cough with *yellow sputum* • Common association with CF, IVDA, hemorrhagic pulmonary edema, and abscess formation • Tension pneumatocyst leads to tension pneumothorax • Pneumatoceles: Thin-walled air-filled cysts that develop in the lung parenchyma, usually after pneumonia
Corynebacterium diphtheriae	• Gram-positive rod • Toxin inhibits protein synthesis by ADP-ribosylation of elongation factor-2 involved in protein synthesis • Toxin also impairs β-oxidation of fatty acids in the heart and may lead to toxic myocarditis • Toxin-induced pseudomembranous inflammation produces shaggy gray membranes in the oropharaynx and trachea • Treatment: Erythromycin
Haemophilus influenzae	• Gram-negative rod • Common cause of sinusitis, otitis media, and conjunctivitis (pink-eye) • Inspiratory stridor may be due to acute epiglottitis • "Thumbprint sign" on lateral x-ray of the neck • *Most common bacterial cause of acute exacerbation of COPD* • Treatment: Cefotoxime; ceftriaxone
Pseudomonas aeruginosa	• Green sputum (pyocyanin) • Water-loving bacteria most often transmitted by respirators • Most common cause of nosocomial pneumonia and death due to pneumonia in cystic fibrosis • Pneumonia often associated with infarction due to vessel invasion • Treatment: Antipseudomonal Beta-lactam + aminoglycoside + antipseudomonal quinolone or macrolide
Klebsiella pneumoniae	• Gram-negative fat rod surrounded by a mucoid capsule • Typical lobar consolidation commonly associated with blood-tinged, thick, mucoid sputum • Productive cough with mucoid sputum • Most common cause of typical lobar pneumonia found in the elderly, especially in nursing homes • Commonly associated with alcoholics
Legionella pneumophila	• Gram-negative rod that stains with silver stain • Hydrophilic organism that is found in ship water coolers; *mists* of various locations, including rain forests of zoos; produce section of grocery stores; and outdoor summertime cooling fans • May produce tubulointerstitial disease with destruction of JG apparatus resulting in hyporeninemic hypoaldosteronism, a type IV renal tubular acidosis • Urine antigen test excellent for screening

Photo Credits (top to bottom): CDC/PHANIE/Science Source; Michael Abbey/Science Source; Science Source

© DeVry/Becker Educational Development Corp. All rights reserved.

▼ **Table 12–6.2 Typical Pneumonia Pathogens** *(continued)*

Typical Pneumonia Pathogens	High-Yield Comments
Bacillus anthracis	• Gram-positive rod resides in soil • Capsule inhibits phagocytosis • Exotoxin — Edema factor activates adenylate cyclase — Lethal factor inhibits signal transduction protein involved in cellular division — Protective antigen assists entry of toxins into cells • Transmission: Direct contact with animal skins or products (most commonly sheep and cattle) and entry of the organism through abrasions • May also be used in germ warfare in which inhalation would be route of entry • **Cutaneous anthrax:** 90%–95% of cases occur through direct contact of contaminated animal product — Resembles insect bite but eventually swells to form a black scab, or eschar, with a central area of necrosis (malignant pustule) — If left untreated, death occurs in 20% of patients • **Pulmonary anthrax:** "First sign of the disease is death" — Inhalation of spores present in contaminated hides or biological weapon — Necrotizing pneumonia, meningitis, pronounced splenomegaly, and dissemination throughout the remainder of the body • Prevention: Vaccines available for high-risk patients, e.g., veterinarians, soldiers entering developing countries • Treatment: Ciprofloxacin
Actinomyces israelii	• Gram-positive filamentous bacteria; strict anaerobe; normal flora in tonsils and adenoids • Producing draining sinuses in the jaw, chest cavity, and abdomen • Pus contains sulfur granules (yellow specks) that contain the bacteria • Treatment: Ampicillin or penicillin G
Nocardia asteroids	• Gram-positive catalase + filamentous bacteria • Strict aerobe and partially acid-fast • Produces granulomatous microabscesses in the lungs • Frequently disseminates to the CNS and the kidney • Treatment: TMP-SMX
Bordetella pertussis	• Gram-negative rod • Pili attach to cilia in upper respiratory tract • Toxin stimulates adenylate cyclase, which catalyzes the addition of ADP-ribose to the inhibitory subunit of the G protein complex • Toxin also produces absolute lymphocytosis, often in leukemoid range • Produces whooping cough, transmitted by droplet infection • **Catarrhal phase:** Lasts 1-2 weeks; mild coughing, rhinorrhea, conjunctivitis • **Paroxysmal coughing phase:** Lasts 2-5 weeks; characterstic 4-5 coughs in succession on expiration followed by inspiratory whoop; absolute lymphocytosis (20,000-50,000 cells/mm^3) • **Convalescense phase:** Lasts 1-2 weeks; slow decline in coughing and lymphocytosis • Complications: — Persistent coughing may cause hemorrhage into skin, conjunctiva, bronchus, and brain; the increased pressure may also cause rectal prolapse — Meningoencephalitis may be seen in 10% of the population; otitis media — Pneumonia is the most common cause of death in children <3 years of age since children <1 year old have no protection from mother's immunoglobulin • Diagnosis: Nasopharyngeal swabs using special cough plate: direct immunofluorescence of swab material • Treatment: Erythromycin

© DeVry/Becker Educational Development Corp. All rights reserved.

▼Table 12–6.2 Typical Pneumonia Pathogens *(continued)*

Typical Pneumonia Pathogens	High-Yield Comments
Moraxella catarrhalis	• Gram-negative diplococcus • Common cause of typical pneumonia in the elderly • *Second most common pathogen causing acute exacerbation of COPD* • Common cause of chronic bronchitis, sinusitis, otitis media • Treatment: Amoxicillin-clavulanate
Yersinia pestis	• Gram-negative rod • Three types of disease (plague): **1.** Bubonic: — Most common — Transmitted via bite by rat flea that has recently bitten an infected ground squirrel — Infected lymph nodes enlarge, usually in the groin, mate together, and drain to the surface (bubuoes) **2.** Pneumonic: Transmitted by aerosol **3.** Septicemic
Fungi	
Cryptococcus neoformans 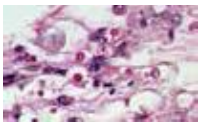	• Budding yeast with narrow-based buds, thick capsule • Look for roosting pigeons outside office windows, under bridges, and pigeon breeders • Primary lung disease in 40% of the cases with caseating granulomas; infected do not have to be immunocompromised • Treatment: Fluconazole

Aspergillus fumigatus	• Fruiting body and narrow-angle of <45 degrees with branching septate hyphae
	• **Aspergilloma:** Chest x-ray will show fungal ball that develops in a preexisting cavity in the lung which may be angioinvasive with massive hemoptysis
	• **Allergic bronchopulmonary aspergillosis:** Type I and type III hypersensitivity reaction with increased IgE and eosinophilia
	  • There is intense inflammation of airways and mucus plugs in terminal bronchioles; repeated attacks may lead to bronchiectasis and interstitial lung disease
	  • Treatment with corticosteroids
	• **Vessel invader** with hemorrhagic infarctions and a necrotizing bronchopneumonia
	• Treatment: Voriconazole

Histoplasma capsulatum 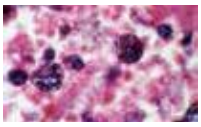	• Most common cause of systemic fungal infections • Found along the path of the Mississippi River; yeasts are found in macrophages • Acquired by inhalation of microconidia in dust contaminated with excreta from bats, in those who are cave explorers (spelunkers); also found in those who have contact with starlings and in chicken farmers • May stimulate TB lung disease; produces coin lesions, consolidations, miliary spread, and cavitation • Marked dystrophic calcification of granulomas; most common cause of multiple calcifications in the spleen • Treatment: Usually self-limited; if severe, itraconazole or liposomoal amphotericin B
Blastomyces dermatitides 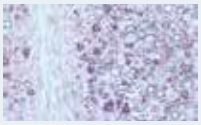	• Yeasts have broad-based buds and nuclei • Occurs in Great Lakes regions, Central and Southeastern U.S. • Most often associated with fishing, hunting, gardening, exposure to beaver dams • Produces skin and lung disease; skin lesions simulate squamous cell carcinoma • Granulomatous inflammation with caseous necrosis • Treatment: Liposomal amphotericin B

Photo Credits (top to bottom): Dr. Gladden Willis/Visuals Unlimited, Inc.; Daniel Snyder/Visuals Unlimited, Inc.; Dr. Cecil H. Fox/Science Source; CNRI/Science Source/Custom Medical Stock Photo;

© DeVry/Becker Educational Development Corp. All rights reserved.

▼**Table 12–6.2** Typical Pneumonia Pathogens *(continued)*

Typical Pneumonia Pathogens	High-Yield Comments
Coccidiodes immitis 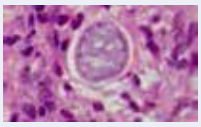	• Spherules with endospores in tissues • Contracted by inhaling arthrospores in dust while living or passing through arid desert areas in the Southwest (valley fever), exposure increased after earthquakes due to soil disturbance • Flu-like symptoms and painful nodules on lower legs representing inflammation of subcutaneous fat known as erythema nodosum • Granulomatous inflammation with caseous necrosis • Treatment: Usually self-limited; if severe, itraconazole or fluconazole
Pneumocystis jiroveci	• Similar to fungi but have no ergosterol in plasma membrane • Cysts and trophozoites present; cysts attach to type I pneumocytes • Primarily an opportunistic infection; occurs when CD4 count <200 cell/mm^3 • Predominantly produces pulmonary disease; patients develop fever, dyspnea, and severe hopoxemia; diffuse intra-alveolar foamy exudates with cup-shaped cysts best visualized with silver or Giemsa stains; chest x-ray shows diffuse alveolar and interstitial infiltrates • Treatment: TMP-SMX given prophylactically when CD4 count <200 cells/mm^3
***Mucor* species**	• Wide-angled hyphae (>45 degrees) without septa • Clinical settings include diabetic or immunosuppressed patients • Vessel invader and produces hemorrhagic infarcts in lung • Invades the frontal lobes in patients with diabetic ketoacidosis (rhinocerebral mucormycosis) • Treatment: Lysosomal amphotericin B

Photo Credits (top to bottom): Michael Abbey/Science Source; C. Abrahams, MD/Custom Medical Stock Photo

6.3 Tuberculosis

6.3.1 Primary Pulmonary Tuberculosis

- Ghon complex:
  - Primary TB with Ghon focus (periphery) and complex (hilar node involvement as well).
  - Progressive spread with cavitation, tuberculous pneumonia, miliary tuberculosis, Pott disease of spine, TB meningitis.

Connection to Microbiology

See *Microbiology*, chapter 3, "Bacteriology" for more discussion of tuberculosis.

6.3.2 Secondary Pulmonary Tuberculosis

- Reactivation TB with atypical cavities; greater degree of damage due to previous sensitization.

Biophoto Associates/Science Source

▲**Figure 12–6.3A** Primary Ghon Complex

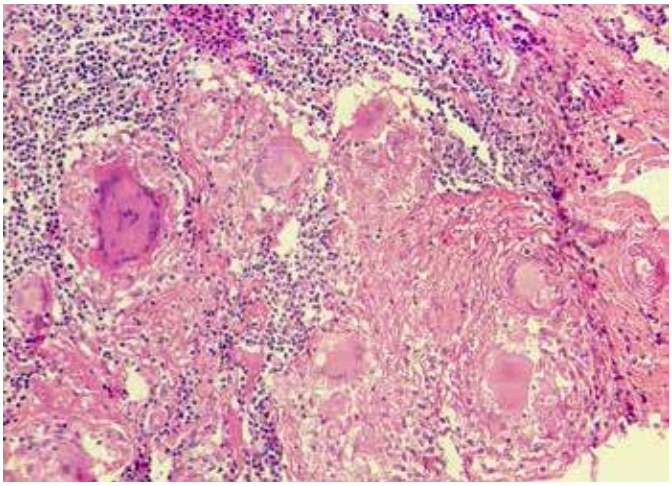

Gary DeLong/Science Source

▲**Figure 12–6.3B** Caseous ("Cheese-Like") Necrosi

© DeVry/Becker Educational Development Corp. All rights reserved.